

Management of a Patient with Apical Hypertrophic Cardiomyopathy with Subacute Intestinal Obstruction

Sreenidi Rangadhamaiah¹, Kiran Nelamangala², Bhaskaran Ashokan³, Lakshmi K Swamy⁴, Threja C Krishnappa⁵, Ravi Madhusudhana⁶

¹Post Graduate Resident, ²Associate Professor, ³Senior Resident, ⁵Assistant Professor, ⁶Professor, Department of Anesthesiology, ³Professor and HOD, Department of Surgery, Sri Devaraj Urs Medical College (SDUMC), Sri Devaraj Urs Academy of Higher Education and Research (SDUAHER), Kolar, Karnataka 563101, India

Abstract

Introduction: Apical Hypertrophic Cardiomyopathy (AHCM) is a rare form of Hypertrophic Cardiomyopathy (HCM) which inherits in autosomal dominant pattern affects 1:500 individual, is localized to left ventricular apex with or without formation of apical aneurysm. Although patients are asymptomatic in resting conditions, anesthesia and surgical stress may lead to exacerbation of the left ventricular outflow tract obstruction (LVOT) obstruction and may complicate perioperative course. *Case Report:* A 65 years old female patient diagnosed with Apical hypertrophic cardiomyopathy presented with primary peritonitis posted for emergency exploratory laparotomy and proceed on Tab Verapamil 160 mg twice daily. We managed this case successfully considering understanding of pathophysiology, hemodynamic changes and anesthetic implications needed for successful perioperative outcome. *Conclusion:* Patients with apical hypertrophic cardiomyopathy undergoing noncardiac surgery require thorough understanding of hemodynamic changes, proper intraoperative vigilance, avoiding factors that may increase left ventricular outflow tract obstruction with proper medication and intravenous fluid therapy.

Keywords: Anesthesia; Apical hypertrophic cardiomyopathy, Intestinal obstruction.

How to cite this article:

Sreenidi Rangadhamaiah, Kiran Nelamangala, Bhaskaran Ashokan et al. Management of a Patient with Apical Hypertrophic Cardiomyopathy with Subacute Intestinal Obstruction. Indian J Anesth Analg. 2019;6(6 Part - II):2256-2259.

Introduction

Apical Hypertrophic Cardiomyopathy (AHCM) is a rare form of hypertrophic cardiomyopathy (HCM) in which hypertrophy is localized to left ventricular apex with or without formation of apical aneurysm. Inherited in autosomal dominant pattern involves mutation in MYBPC3 and MYH7 affects 1:500 individual.^{1,2} Although majority of patients are asymptomatic throughout life, some present with severe limiting symptoms of dyspnoea, angina

and syncope and few may die suddenly because of cardiac arrhythmias. Left Ventricular Outflow Tract obstruction (LVOT) can be precipitated by sympathetic stimulation and decrease in preload and after load to left ventricle,³ Hence, these patients pose higher risk for perioperative events.

Case Report

A 65 years old female patient, weighing 58 kgs presented with complaints of acute pain abdomen

Corresponding Author: Kiran Nelamangala, Associate Professor, Department of Anesthesiology, Sri Devaraj Urs Medical College (SDUMC), Sri Devaraj Urs Academy of Higher Education and Research (SDUAHER), Kolar, Karnataka 563101, India.
E-mail: dr.kiran@gmail.com

Received on 26.08.2019, Accepted on 23.10.2019

since, 1 day, sudden in onset, progressive in nature, not subsided with analgesics and anti-spasmodics, not associated with vomiting, fever and loose stools. She was diagnosed with primary peritonitis posted for emergency exploratory laparotomy and proceed. Past history of irregular bowel habits present since 3 years. She was diagnosed with Apical cardiomyopathy on regular medication (Tab Verapamil 160 mg twice daily) presently asymptomatic and diabetes mellitus under dietary control.

Examination revealed mild pallor, pulse rate of 82/min and blood pressure of 130/90 mm Hg, respiratory rate of 20 per minute and was afebrile. Systemic examination of cardiovascular, respiratory, central nervous system was normal with per abdomen examination of soft abdomen with no guarding or rigidity with presence of upper abdomen distension. Laboratory investigations were normal except for hemoglobin 9.1 gm % and WBC 14,500. Electrocardiogram showed deep negative T waves V1-V6, (Fig. 1).

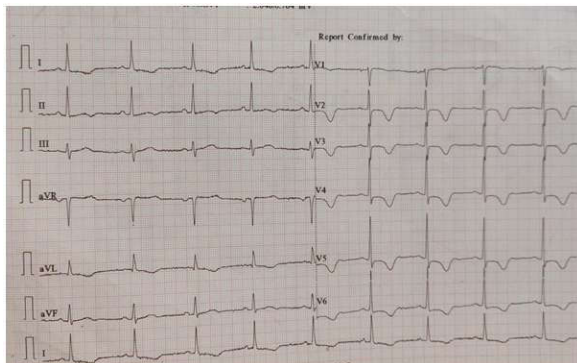


Fig. 1: ECG showing Deep T inversions in V12 to V6 leads

Anesthetic Management

Two 18 G IVC secured in right and left forearm, preloaded with 500 ml RL. Ryle's tube which was *in situ* was aspirated. Monitoring included pulse oximetry, ECG, invasive blood pressure, end-tidal carbon dioxide and urine output. Premedicated with Inj glycopyrrolate 0.2 mg IV, Inj Midazolam 1 mg and Inj fentanyl 80 mcg IV. Preoxygenation done with 100% oxygen for 3 min. Induced with Inj Propofol 100 mg IV. Lignocaine 1.5 mg/kg was given to attenuate stress response. Endotracheal intubation was facilitated with Inj. Scoline 100 mg, intubated with 7.0 size ET tube. Anesthesia was maintained with 50% nitrous oxide in oxygen and atracurium bolus dose 0.5 mg/kg followed by maintenance doses of 0.1 mg/kg, intermittent propofol with intermittent positive pressure

ventilation. Further analgesia was supplemented by Inj Neomol 1 gm IV. Anti-arrhythmic drugs and external defibrillator were kept ready to tackle an inadvertent arrhythmic event inj Dexona 8 mg IV was also given. The hemodynamic parameters were monitored which remained stable throughout the procedure. The procedure lasted for 90 min during which 1.5l of crystalloids was given. Urine output and blood loss was measured.

Surgical findings were Multiple small intestine diverticula with pnuematocoeles which presented as primary peritonitis and stricture at terminal ileum which was repaired with transverse ileoplasty (Figs. 2 and 3).

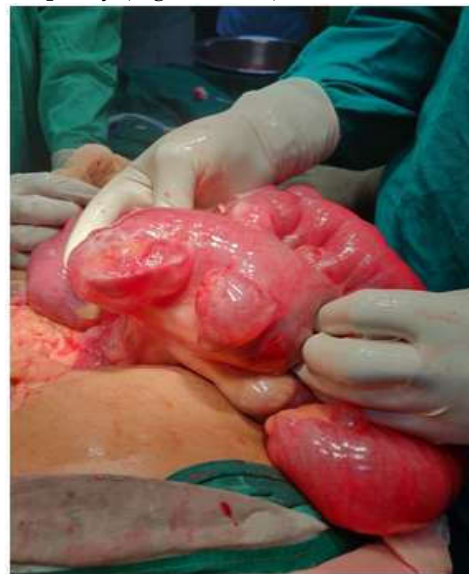

Fig. 2: Small intestine diverticula

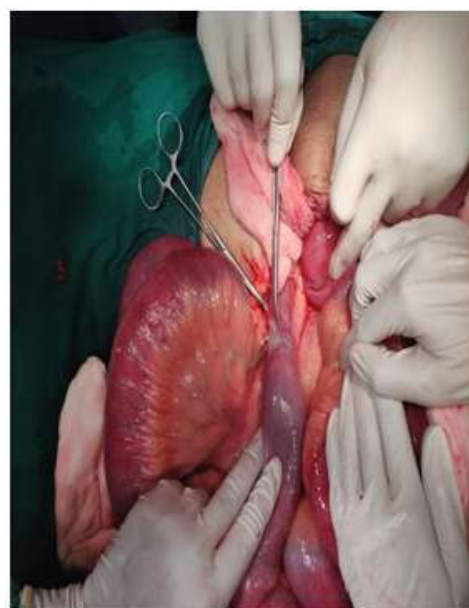


Fig. 3: Stricture at terminal ileum

At the end of surgery ultrasound guided bilateral transversus abdominis plane block was given for postoperative analgesia with Inj Lox 2% + Adrenaline 5cc + Inj Bupivacaine 0.5% 5cc each side, neuromuscular block was reversed with Inj Neostigmine 2.5 mg and Inj Glycopyrrolate 0.4 mg IV and extubated. Shifted to postoperative intensive care unit for further observation and management.

Postoperatively Fentanyl patch was applied, Neomol 1 gm IV TID was continued. 1 PCV was transfused, advised to do Incentive spirometry and fluid management accordingly.

Discussion

Rare form of hypertrophic cardiomyopathy which involves apex of left ventricle.¹ AHCM can be incidental finding, may present with chest pain, palpitation, dyspnoea, syncope, Atrial fibrillation, myocardial infarction, embolic events and congestive heart failure. Inherited in sporadic, autonomic dominant pattern.² Most frequent and classic ECG finding are giant negative T wave in precordial leads. Transthoracic-ECHO is initial diagnostic tool in evaluation of AHCM.

Hypertrophy is most common with upper intraventricular septum, below aortic valve leading to LVOT obstruction. This is accentuated by anterior motion of the septal leaflet of mitral valve, may also be diastolic dysfunction due to prolongation of isovolumetric relaxation time and decrease left ventricular volume. B-blocker and calcium channel blocker have been used to treat HCM.

In one of the case report for elective surgery posted for TURP, balanced general anesthesia using oral diazepam as premedication and induction and maintenance with fentanyl, thiopentone, atracurium, nitrous oxide in oxygen and sevoflurane was used.³

In another case, posted for PCNL with HCM, it was induced with midazolam 1 mg, fentanyl 1100 mcg and propofol 30 mg. Esmolol 30 mg 3 min before intubation to attenuate laryngoscopy response and also repeated during extubation.⁴

In one more case, posted for Modified Radical Neck Dissection, who was a known smoker and hypertensive on oral metoprolol and amlodipine, suddenly developed narrow complex tachycardia with Ventricular tachycardia of 180–200/min. Halothane and nitrous oxide was discontinued and administered 100% oxygen. 3 mg metoprolol was given slowly, when no response was observed diltiazem 10 mg was administered IV and repeated

with diltiazem 15 mg. Ventricular rate decreased to 110/min. Patient was transferred to ICU and put on ventilator with midazolam infusion and Inj metoprolol was continued 5 mg thrice daily for heart rate control.⁵

Goal of anesthetic management in a patient with HCM for non-cardiac surgery is to prevent occurrence of LVOT obstruction, arrhythmias and diastolic dysfunction.^{6,7}

Concerns during anesthesia and surgery are sympathetic stimulation arising out of laryngoscopy and intubation, incision, surgical stress and blood loss. Inappropriate monitoring may worsen dynamic outflow tract obstruction. Management in these patient is directed towards minimizing LVOT obstruction. Preloading before helps maintain stroke volume and minimizes adverse events of positive pressure ventilation. Premedication with midazolam helps alleviating anxiety and thus avoiding unnecessary sympathetic stimulation. Aggressive maintenance of sinus rhythm, maintaining preload and after load with selective alpha-1 agonist like phenylephrine preferred over ephedrine as it increases SVR without significant effect on myocardial oxygen demand and HR, administration of B-blocker or verapamil and suppression of sympathetic stimulation.

Conclusion

Patients with apical hypertrophic cardiomyopathy undergoing non-cardiac surgery require thorough understanding of hemodynamic changes, proper intraoperative vigilance, avoiding factors that may increase Left Ventricular Outflow Tract obstruction (LVOT) with proper medication and intravenous fluid therapy.

Key Messages

Managing anesthesia in a patient with Apical hypertrophic cardiomyopathy can be very challenging with obstructive symptoms, in our patient Verapamil was used for rate control and for avoiding tachy-arrhythmias because tachycardia is not tolerated well in these patients, this can reduce cardiac output. Our patient presented with symptoms of acute abdomen with fluid levels in intestines and mild tachycardia and anesthesia was planned meticulously and the outcome was good.

Prior publication: Nil

Support: Nil

Conflicts of interest: Nil

Permissions: Nil

References

1. Fuad JM, Maria CT, Lilia O, *et al.* Apical hypertrophic cardiomyopathy: Present status. *Int J Cardiol.* 2016;222:745-59.
2. Yuichiro M, Shintaro H, Nobuhisa H. Phenotypic overlap in hypertrophic cardiomyopathy: Apical hypertrophy, midventricular obstruction, and apical aneurysm. *J Cardiol.* 2014;64:463-69.
3. Jain A, Jain K, Bhagat H, *et al.* Anesthetic management of a patient with hypertrophic obstructive cardiomyopathy with dual-chamber pacemaker undergoing transurethral resection of the prostate. *Ann Card Anesth.* 2010;13:246-48.
4. Nama RK, Parikh GP, Patel HR. Anesthetic management of a patient with hypertrophic cardiomyopathy with atrial flutter posted for percutaneous nephrolithotomy. *Anesth Essays Res.* 2015;9:284-86.
5. Sahoo RK, Dash SK, Rout PS, *et al.* Perioperative anesthetic management of patients with hypertrophic cardiomyopathy for noncardiac surgery: A case series. *Ann Card Anesth.* 2010;13:253-56.
6. Poliac LC, Barron ME, Maron BJ. Hypertrophic cardiomyopathy. *Anesthesiology.* 2006;104:183-92.
7. Haering JM, Comunale ME, Parker RA, *et al.* Cardiac risk of noncardiac surgery in patients with asymmetric septal hypertrophy. *Anesthesiology.* 1996;85:254-59.

